



# The Effect of Computed Tomography on Surgeon's Decisions in Suspected Appendicitis Cases

## Şüpheli Apendisit Olgularında Bilgisayarlı Tomografinin Cerrahin Kararları Üzerine Etkisi

Tomografinin Cerrahin Kararına Etkisi / The Effect of Tomography on Surgeon's Decisions

Alaattin Öztürk<sup>1</sup>, Hakan Bozkurtoglu<sup>2</sup>, Yeşim Üçkurt<sup>3</sup>, Cengiz Kaya<sup>4</sup>, Zuhale Demirhan Yananlı<sup>1</sup>, Ömer Faruk Akıncı<sup>1</sup>

<sup>1</sup>Fatih Üniversitesi Tıp Fakültesi, Genel Cerrahi Kliniği, Ankara, <sup>2</sup>Central Hospital, Genel Cerrahi Kliniği, İzmir,

<sup>3</sup>Fatih Üniversitesi Tıp Fakültesi, Radyoloji Kliniği, Ankara, <sup>4</sup>Pendik Devlet Hastanesi, Genel Cerrahi Kliniği, İstanbul, Türkiye

### Özet

**Amaç:** Bu çalışmanın amacı, şüpheli apandisit hastalarında, cerrahin teşhis ve tedavi kararları üzerindeki tomografinin etkilerini belirlemektir. **Gereç ve Yöntem:** Çalışmamız 2010 – 2011 tarihleri arasında yapıldı. Apendisit olduğundan şüphelenilen ve batin tomografisi (BT) çekilen 125 hasta çalışmaya alındı. Tomografi çekiminin cerrahin teşhis ve tedavi kararları üzerindeki etkileri değerlendirildi. **Bulgular:** BT sonucunda 89 hastada apandisit bulguları belirlendi, 36 hastada apandisit bulgusu belirlenemedi. BT'de apandisit bulguları belirlenen hastaların 88'i ve BT'de apandisit bulgusu olmayan 5 hasta (toplam 93 hasta) ameliyat edildi. Histopatolojik incelemeye göre 83 hastada apandisit bulguları belirlendi, 10 hastada apandisit görülmedi. Çalışmamız sonucuna göre BT, şüpheli apandisit olan 98 hastada (%78,4) teşhis ve tedavi planının değişmesine sebep olmuştur. Bu hastaların 65'inde (%52) apandisit teşhisi kesinleşmiş, gözlem sonlandırılıp tedaviye geçilmiştir, 33 hastada hem teşhis hem tedavi planı değişmiştir. 27 hastada (%21,6) ise BT cerrahin kararlarına etki etmemiştir. **Tartışma:** BT, şüpheli apandisit hastalarında teşhis ve tedavi kararını etkileyen bir teşhis yöntemidir. Akut apandisit şüpheli hastalarda beklemeksizin BT çekimi yapılmasını öneriyoruz.

### Anahtar Kelimeler

Apendektomi; Tomografi; Karın Ağrısı

### Abstract

**Aim:** The purpose of this study is to evaluate the effect of computed tomography (CT) on the diagnosis and treatment plan of surgeons in patients with suspected appendicitis. **Material and Method:** Our study was conducted between 2010 – 2011. One hundred twenty five patients suspected appendicitis and underwent abdominal computed tomography scanning were enrolled. The effects of CT scanning on the diagnosis and treatment plan of surgeons were evaluated. **Results:** After CT scanning the findings of appendicitis was revealed in 89 patients were not revealed in 36. Eighty eight patients diagnosed with acute appendicitis after a CT scan and the 5 patients with clinical suspect of appendicitis which is not confirmed by CT scan were operated (total 93 patients). In according to histopathological findings acute appendicitis were confirmed in 83 patients and were not confirmed acute appendicitis in 10 patients. According to our study, CT has changed the diagnosis and treatment plan in 98 patients (78.4%) with suspected appendicitis. The diagnosis of acute appendicitis was confirmed in 65 (52%) of these patients, and treatment was started ending the observation. Diagnostic and treatment plan was changed in 33 patients and CT did not affect surgeon's decision in 27 (21.6%) patients. **Discussion:** CT is a diagnostic method which affects the diagnosis and treatment of patients with suspected appendicitis. We recommend CT scans without waiting in patients with suspected acute appendicitis.

### Keywords

Appendectomy; Tomography; Abdominal Pain

DOI: 10.4328/JCAM.2382

Received: 11.03.2014 Accepted: 27.03.2014 Printed: 01.11.2015 J Clin Anal Med 2015;6(6): 716-9

Corresponding Author: Alaattin Öztürk, Fatih Üniversitesi Tıp Fakültesi, Genel Cerrahi Kliniği, Yalı Mh. Sahil Yolu Sk. No:16 34844 Maltepe, İstanbul, Türkiye.

T.: +90 2164589000 F.: +90 2163528359 GSM: +905324156301 E-Mail: aloz1969@yahoo.com

## Introduction

Acute appendicitis (AA) is a frequent surgical disease. A physical examination, complete blood count, and sometimes ultrasonography (US) are usually sufficient to diagnose AA. If these investigations are not sufficient, abdominal computed tomography (CT) can be used to diagnose. CT has exceeds 90% sensitivity and specificity in diagnosis for AA [1]. But routine use of CT is still controversial.

There are many studies which evaluated the benefit of CT in diagnosing appendicitis, but only a few studies describe how CT use affected the surgeon's decisions in suspected appendicitis. Some studies have reported that CT has a contribution in diagnosis, while others have reported that CT is unnecessary or even harmful [2].

In this study, we tried to examine the effect of abdominal CT on the diagnosis and treatment in patients with suspected appendicitis.

## Material and Method

This prospective study was conducted prospectively between July 2010 and November 2011. The study was approved by the local ethics committee. One hundred twenty five patients with suspected appendicitis and abdominal CT scan were enrolled. Patients who had a definitive diagnosis and treatment without the use of a CT scan were excluded.

Patients' complaints and physical examination findings, complete blood count, urinalysis, plain abdominal X-ray and US results were recorded. After diagnostic tests, suspected AA was determined for patients. An abdominal CT was performed to clarify the diagnosis in patients. The reasons for CT scanning are listed in table 1.

Table 1. Reasons for CT scan (n: number of patient)

Reasons for CT scan	n
Inadequate evidence for appendicitis	52
Inadequate US results to diagnosis	31
Exclusion of other diseases	22
Patient's request	7
Obesity	5
Others	8
Total	125

Multi-slice CT without contrast was performed for all patients. CT images were assessed immediately by radiologists after the scanning. The diagnostic criteria for AA on CT were the expansion of the appendix diameter more than 8 mm, the presence of appendicolith, periappendicular fluid collection, increased thickness of the appendix wall, and the appearance of inflammation in mesoappendix. The management of patients was planned according to the result of the CT.

Patients with at least one of these findings in abdominal CT scan in addition to clinical signs and symptoms were diagnosed with AA. Patients with diagnosis of AA were operated upon. The remaining patients were given medical treatment.

The diagnosis before and after the CT scan and the effects of using a CT scan on surgeon's treatment plan was recorded. The results of the surgery and pathologic findings were also recorded. Pathological results were compared with the preoperative

diagnosis. Patients with histopathologically normal appendixes and those having non-appendicitis pathology were classified as negative appendectomy.

## Results

During the study period, 243 patients were operated because of appendicitis and 125 of these patients were enrolled in the study. The median age of the patients were 33 (range 5-85 years), and 73 (58,4%) were male and 52 (41,6%) were female. The most common reason for CT scanning was a need of confirmation for clinical suspect of AA (52 patients). After CT scanning, the most frequent radiologic diagnosis was AA (89 patients). CT scan findings were not compatible with AA in 36 patients. No pathological finding was seen in CT scan of 14 patients in this group and there were other pathologies in 22. Eighty eight patients diagnosed with AA after a CT scan and the 5 patients with clinical suspect of appendicitis which is not confirmed by CT scan were operated (total 93 patients). One patient with radiologic findings of AA was not operated due to inadequate clinical findings (Figure 1). According to the results

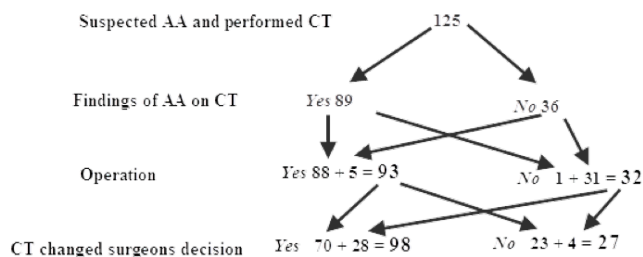


Figure 1. The results of patients.

of histopathology, AA was confirmed in 83 patients except for 10, including 6 normal appendixes, two inflammation of epiploic appendix, one cecal perforation, and one ovarian cyst rupture. AA was revealed in four of five patients whose operated according to clinical findings. Histopathologic findings in operated patients are given in table 2. According to the results of histopathology, the negative appendectomy rate in the study was 10.8%.

Table 2. Results of histopathology of patients who underwent surgery

Histopathology	Findings of AA on CT	Not Findings of AA on CT	Total
Appendicitis	79	4	83
Not appendicitis	9	1	10
Total	88	5	93

The use of CT changed the clinical diagnosis and treatment plan of surgeon in 98 patients (78.4%), but had no effect in 27 patients (21.6%). The most important effect of CT was to determinate an ultimate diagnosis and to terminate the observation (%52). Eighteen of the 27 patients whose treatment plan was not changed by their CT results had appendicitis and 9 had other diagnoses (Table 3).

Seven (25.9%) of the 27 patients whose treatment plan was not changed by CT scan were female and 20 (74.1%) were male. Forty-five (45.9%) of the 98 patients whose treatment has been changed by CT scan were female and 53 (54.1%) were male.

Table 3. The effect of CT on diagnosis and treatment strategy. (n: number of patients)

	Affected by CT (n=98)	Unaffected by CT (n=27)
	n (%)	
Appendicitis became ultimate diagnosis	65 (52%)	
The operation was abandoned	24 (19.2%)	
Incision was changed	3 (2.4%)	27 (21.6%)
Other changes	6 (4.8%)	
Total	98 (78.4%)	

In our study, the sensitivity, specificity, positive predictive value, negative predictive value and the overall accuracy of CT were 95.1%, 76.1%, 98.7%, 88.8% and 88.8% respectively.

## Discussion

Appendicitis is the most frequently diagnosed disease in patients with right lower quadrant abdominal pain. Detecting the presence or absence of acute appendicitis is essential for treatment planning.

CT scans may not be necessary for every patient presenting with abdominal pain, but it can be useful in making a definitive diagnosis when other investigation methods are not adequate for diagnosis or when exclusion of other pathologies are required. The surgeon generally makes a pre-diagnosis and treatment plan before CT scanning in patients presenting with abdominal pain. It is important to understand how the CT scan affects this process, because it could encourage routine use of CT scans in these cases.

The increased rate of negative appendectomy has led to a search for more efficient methods for accurate diagnosis. The use of CT, especially in suspicious cases, was found to decrease the rate of negative appendectomy. Studies have shown that while the rate of negative appendectomy without CT was 16-24%, CT use decreased it to 5% [1,3,4]. A meta-analysis found that negative appendectomy pre-CT was 21.5% but decreased to 10% with the use of CT scans. We found that the rate of negative appendectomy is 10.8%. CT was found to be more helpful in female patients [4]. In a study by Coursey et al, the use of CT was found to decrease the rate of negative appendectomy only in female patients younger than 45 years of age. The rate was similar in males and older females [5]. However, some studies did not find any significant difference with the use of CT [6].

The sensitivity and specificity of CT for diagnosis of appendicitis is quite high, and reported to be 87-100% and 83-100% respectively [3,7,8]. The overall accuracy, positive predictive value and negative predictive value of CT were reported to be 94-98%, 92-98% and 95-100% respectively [8,9]. We found similar results in our study.

Although the use of intravenous contrast material is advised for the diagnosis of appendicitis, unenhanced CT scans may also be used [10]. We did not use contrast in patients, and preferred not to use contrast materials when possible because oral and rectal contrast material use is time-consuming and uncomfortable for patients. Oral, intravenous, and rectal contrast materials can be used depending on the individual patient's clinical status. In one study, where a definitive diagnosis was made in 75% of patients, contrast CT was reserved for those who could

not be diagnosed by plain CT [11].

The effect of CT on treatment plans is quite high because of its high sensitivity and specificity. In one study, it was found that CT influenced the diagnosis and/or treatment of 45.6% of patients [10]. In our study, this value was 78.4% (98 patients). This high rate is expected because definitive diagnosis was not made with other tests and the CT scan was expected to aid in the diagnosis and treatment planning process.

Other studies showed that CT affects the treatment of appendicitis by avoidance of unnecessary appendectomy, avoidance of unnecessary observations, and exclusion of other pathologies [1,10,12,13]. By avoiding unnecessary operations, CT reduces the cost of treatment [14]. Especially appendagitis epiploica located in the right colon should be considered in the differential diagnosis. Because acute appendicitis need surgical intervention while epiploic appendagitis can be recovered by medical treatment [15,16]. The differential diagnosis of these two diseases can be made by CT. In our study, the most common effect of CT was a more definitive diagnosis of appendicitis. As a result, the surgeon started the surgery with a more accurate diagnosis and the patients consented to the operation more easily. Another effect of CT is the change of the incision; this change is important because control of a large area is needed when the CT shows a perforated appendicitis.

Abdominal CT seems to reduce the rates of perforated appendicitis by eliminating unnecessary follow-up and time loss in some patients. However, the CT scanning did not change the rates of perforated appendicitis [1]. There is a concern that the use of CT may be an unnecessary waste of time and increase the rate of perforated appendicitis [14]. In our study, we found perforated appendicitis in a total of 16 patients (19.2%); As CT scanning is a quick procedure, requiring approximately 15 minutes in our hospital, we consider that this minimal time delay does not contribute to the development of perforation with appendicitis. Some studies showed that false negative diagnosis of acute appendicitis by CT can lead to delayed surgical treatment [5]. In our study, 5 patients were operated upon according to clinical findings, although CT findings were negative for appendicitis. Histopathological evaluations confirmed acute appendicitis in 4 of these 5 patients.

## Conclusion

The use of CT in suspicious appendicitis cases affected the surgeon's diagnosis and treatment strategy in 98 (78.4%) cases and had no effect in 27 (21.6%) cases. The diagnosis was changed in 52% of patients and the treatment strategy in 26.4% of patients. We suggest that CT improved the judgment of the surgeons. This improvement is seen as more definitive diagnosis of appendicitis, avoidance of unnecessary surgery, or in modification of the incision.

## Acknowledgement

We thank to Kristin Öztürk for helping English translation of this article.

## Competing interests

The authors declare that they have no competing interests.

**References**

1. Hershko DD, Sroka G, Bahouth H, Ghersin E, Mahajna A, Krausz MM. The role of selective computed tomography in the diagnosis and management of suspected acute appendicitis. *Am Surg* 2002;68(11):1003-7.
2. Lee SL, Walsh AJ, Ho HS. Computed tomography and ultrasonography do not improve and may delay the diagnosis and treatment of acute appendicitis. *Arch Surg* 2001;136(5):556-62.
3. McGory ML, Zingmond DS, Nanayakkara D, Maggard MA, Ko CY. Negative appendectomy rate: influence of CT scans. *Am Surg* 2005;71:803-8.
4. Krajewski S, Brown J, Phang PT, Raval M, Brown CJ. Impact of computed tomography of the abdomen on clinical outcomes in patients with acute right lower quadrant pain: a meta-analysis. *Can J Surg* 2011;54(1):43-53.
5. Coursey CA, Nelson RC, Patel MB, Cochran C, Dodd LG, DeLong DM, et al. Making the diagnosis of acute appendicitis: do more preoperative CT scans mean fewer negative appendectomies? A 10-year study. *Radiology* 2010;254(2):460-8.
6. Petrosyan M, Estrada J, Chan S, Somers S, Yacoub WN, Kelson RL, et al. CT scan in patients with suspected appendicitis: clinical implications for the acute care surgeon. *Eur Surg Res* 2008;40(2):211-9.
7. Schuler JG, Shortsleeve MJ, Goldenson RS, Perez-Rossello JM, Perlmutter RA, Thorsen A. Is there a role for abdominal computed tomographic scans in appendicitis? *Arch Surg* 1998;133:373-6.
8. Ege G, Akman H, Sahin A, Bugra D, Kuzucu K. Diagnostic value of unenhanced helical CT in adult patients with suspected acute appendicitis. *Br J Radiol* 2002;75(897):721-5.
9. Nathan RO, Blackmore CC, Jarvik JG. Therapeutic impact of CT of the appendix in a community hospital emergency department. *AJR Am J Roentgenol* 2008;191(4):1102-5.
10. Tsushima Y, Yamada S, Aoki J, Motojima T, Endo K. Effect of contrast-enhanced computed tomography on diagnosis and management of acute abdomen in adults. *Clin Radiol* 2002;57(6):507-13.
11. Santos DA, Manunga J Jr, Hohman D, Avik E, Taylor EW. How often does computed tomography change the management of acute appendicitis? *Am Surg* 2009;75(10):918-21.
12. Siewert B, Raptopoulos V, Mueller MF, Rosen MP, Steer M. Impact of CT on diagnosis and management of acute abdomen in patients initially treated without surgery. *AJR Am J Roentgenol* 1997;168(1):173-8.
13. Rao PM, Rhea JT, Novelline RA, Mostafavi AA, McCabe CC. Effect of computed tomography of the appendix on treatment of patients and use of hospital resources. *N Engl J Med* 1998 15;338(3):141-6.
14. Musunuru S, Chen H, Rikkers LF, Weber SM. Computed tomography in the diagnosis of acute appendicitis: definitive or detrimental? *J Gastrointest Surg* 2007;11(11):1417-21.
15. İnan, N Arslan A. Primary Epiplöic Appendagitis: CT Findings: Case Report. *Türkiye Klinikleri J Gastroenterohepatol* 2010;17(2):115-7.
16. Akgün V, Sağlam M, Örs F, Battal B, Öztürk E, Şimşek A. Acute Epiplöic Appendagitis: Tissue Harmonic Ultrasonography and Computed Tomography Imaging Features in Two Cases. *Türkiye Klinikleri J Med Sci* 2010;30(5):1716-9.

**How to cite this article:**

Öztürk A, Bozkurtoglu H, Üçkurt Y, Kaya C, Yananlı ZD, Akıncı ÖF. The Effect of Computed Tomography on Surgeon's Decisions in Suspected Appendicitis Cases. *J Clin Anal Med* 2015;6(6): 716-9.